

# Tethered oral tissues as a differential diagnostic tool in infants and toddlers presenting with obstructive sleep apnoea and air induced reflux

Lawrence Kotlow

Practice Limited to Pediatric Dentistry, 340 Fuller Road Albany, New York, USA

---

## BRIEF REPORT

---

Please cite this paper as: Kotlow L. Tethered oral tissues as a differential diagnostic tool in infants and toddlers presenting with obstructive sleep apnoea and air induced reflux. AMJ 2019;12(5):131–137.

<https://doi.org/10.21767/AMJ.2019.3579>

---

### Corresponding Author:

Lawrence Kotlow DDS

Practice Limited to Pediatric Dentistry,

340 Fuller Road. Albany. New York 12203. USA

Email: [kiddsteeth@aol.com](mailto:kiddsteeth@aol.com)

---

## ABSTRACT

---

### Background

Paediatric dentists treating infants presenting with symptoms of gastroesophageal reflux or sleep apnoea can see a clinical improvements of symptoms of over 90 per cent in both air induced reflux and OSA.

### Aims

The purpose of this paper is to open the eyes of the medical profession and health care community on need to understand that the ankylosed tongue needs to be included a differential diagnosis when evaluating infants having symptoms suggesting gastroesophageal reflux and obstructive sleep apnoea.

### Methods

Surgical revisions using the 9300nm Carbon dioxide laser without the need for general anaesthetics in the dental office.

### Results

Resolution or reduction of these problems often related to the tethered oral tissues can be seen in over 90 per cent of infants within 24-48 hours.

### Conclusion

Air induced reflux and Obstructive sleep disordered breathing are often the consequence of the ankylosed tongue and if allowed to go untreated can allow developmental problems which can last a life time. This may be a factor in the development of attention deficit disorder and attention-deficit/hyperactivity disorder (ADD and ADHD) in children. Early intervention can potentially intercept this from occurring.

### Key Words

Reflux, OSA, ankyloglossia

---

### Implications for Practice:

#### 1. What is known about this subject?

Unfortunately the medical community ignores the plethora of scientific information relating tethered oral tissues (TOTS) to obstructive sleep apnoea (OSA) and air induced reflux (AIR)

#### 2. What new information is offered in this report?

Hopefully to wake up the medical community the merging of dental medicine and medicine and need for both professions to work together for the benefit of out patients

#### 3. What are the implications for research, policy, or practice?

Saving the breastfeeding dyad the pain and suffering which is easily and safely corrected in then dental office. More peer reviewed ethical studies should be performed to further validate clinical effectiveness seen when these problems are treated by the release of tethered oral tissues.

---

### Background

Over 2000 years ago Aulus Cornelius Celsus in his book De Medicina described the tongue being tied down from birth and the affect it can have on speech and the release of the membrane holding it down.<sup>1</sup> The benefits of breastfeeding are well documented.<sup>2</sup> However the idea that the tethered tongue may be a factor in other developing difficulties other

than preventing an infant to achieve a secure latch is often misdiagnosed or ignored completely.

There are many signs that an infant/mother dyad are struggling to successfully breastfeed.<sup>3,4</sup> The purpose of this article is to increase awareness that two specific symptoms which are most often related to tethered oral tissue especially the ankylosed tongue.<sup>5</sup> The tethered tongue should to be considered as part of any medical differential diagnosis when obstructive sleep apnoea (OSA) or infant reflux is present before invasive surgical procedures such as stomach feeding tubes, or endoscopies are completed under a general anaesthetic, placement of nasal tubes for feeding, hospitalization for failure to thrive, placement on adult anti-reflux medication or continuous positive airway pressure (CPAP) devices are used.

#### **Air induced reflux**

During an accurate clinical exam to determine whether or not the presence of any tethered oral tissues exist, the infant's head should place on the examiner's lap facing forward, not just a looking at the infant's mouth on the mother's lap. When taking a good breastfeeding history, a series of symptoms may be evident and can be considered the result of an infant failing to achieve a secure latch onto the mother's breast. This results in the infant swallowing air in to the stomach. Part of the infant's initial medical examination must include a questioner which lists potential dyad symptoms:

#### **Mother's symptoms**

1. Painful latching of infant onto the breast
2. Gumming or chewing of the nipples
3. Bleeding, cracked or cut nipples
4. Infant unable to achieve a successful, tight latch
5. Poor or incomplete breast drainage
6. Infected nipples or breasts
7. Abraded nipples
8. Plugged Ducts
9. Mastitis
10. Nipple Thrush
11. Feelings of depression
12. Over supply of breast milk
13. Breast abscess

#### **Infant's Symptoms**

1. Difficulty in achieving a good latch
2. Falls to sleep while attempting to nurse
3. Slides off the breast when attempting to latch
4. Aerophagia (clicking, swallowing air during nursing)
5. Poor weight gain

6. Short sleep episodes (feeding every 1–2 hours)
7. Apnoea- snoring, heavy noisy breathing
8. Unable to keep a pacifier in the infant's mouth
9. Waking up congested in the morning
10. Only sleeping when held upright position, in car seat
11. Gagging when attempting to introduce solid foods
12. Milk leaking out sides of mouth during feedings

It is not necessary to differentiate between gastroesophageal reflux and gastroesophageal reflux disease (GER and GERD) for the purpose of this article since it appears most physicians treat both similarly.<sup>6</sup> According to studies, infant reflux can affect as many as 40–65 per cent of babies and most grow out of it by 12–18 months. In recent years, physicians have been increasingly prescribing powerful stomach-acid suppressors, such as proton pump inhibitors (PPIs) and histamine receptor antagonists (H2 blockers), to otherwise healthy infants with gastroesophageal reflux (GER). Evidence suggests these drugs don't reduce symptoms of reflux in infants or crying and irritability in infants that is often presumed to be a sign of reflux. Safety concerns have also emerged with findings that suggest giving these drugs to infants younger than 6 months of age can be associated with a higher risk of bone fractures later in childhood.

Medications like ranitidine (Zantac) or omeprazole (Prilosec) may prevent absorption of calcium and iron, and increase the risk intestinal and respiratory infections. The United States Food and Drug Administration (USFDA) has not approved these drugs for children under age one for any indications.

The paediatric dentist is in a unique position to help these parents and babies. Increasingly, mothers presenting with the reflux symptoms are seeking non-invasive and non-pharmacologic care by revisions of tethered oral tissues in the dental office. In the author's study of 1000 infant who returned a post-revision questioner after the tethered oral tissue revisions, who had indicated the presence of symptoms of reflux and using the above-mentioned drugs without any success 92 per cent showed improvement within 24–48 hours after laser revisions of the tethered oral tissues (Figure 1).

Evidence-based medicine requires clinicians to integrate valid and useful evidence with clinical expertise. Too often these mothers are screaming to be helped and their physician is unable to identify a physical cause for the symptoms and turns reflexively to first time mothers, as related to stress or anxiety as the explanation, rather than

address the root causes of infant and mother distress, thousands of dollars are wasted treating the symptoms, and mothers and infants are allowed to needlessly suffer. Incorrect diagnosis suggests infants are congested due to an allergy to mother's diet when perhaps is due to a poor latch & silent reflux? Is an infant suffering from gas and reflux for 4–18 months really healthy, content and growing well? When a mother has to endure those hellish hours between darkness and dawn when her husband and she would take turns walking around the house with their baby in their arms, praying and mostly sobbing because they couldn't console their infant.

A search of existing literature indicates insufficient evidence to support the routine use of prokinetic agents for gastroesophageal reflux and gastroesophageal reflux disease GERD in children.

Suggested treatment from the Mayo clinic website for GERD or GER.

(<https://www.mayoclinic.org/diseases-conditions/infant-acid-reflux/symptoms-causes>)

- Infant reflux usually clears up by itself. In the meantime, your doctor might recommend:
- Giving your baby smaller, more-frequent feedings.
- Interrupting feedings to burp your baby.
- Holding your baby upright for 20–30 minutes after feedings.
- Eliminating dairy products, beef or eggs from your diet if you're breast-feeding, to test if your baby has an allergy.
- Switching the type of formula, you feed your baby.
- Using a different size of nipple on baby bottles. A nipple that is too large or too small can cause your baby to swallow air.
- Thickening formula or expressed breast milk slightly and in gradual increments with rice cereal. Although recognized as a reasonable strategy, thickening adds potentially unnecessary calories to your baby's diet.
- Nowhere does the mention of ankyloglossia or other tethered oral tissues get discussed as part of the differential diagnosis.

If that doesn't work then more invasive tests may be suggested:

- Ultrasound. This imaging test can detect pyloric stenosis.

- Lab tests. Blood and urine tests can help identify or rule out possible causes of recurring vomiting and poor weight gain.
- Oesophageal pH monitoring. To measure the acidity in your baby's oesophagus, the doctor will insert a thin tube through the baby's nose or mouth and into the oesophagus. The tube is attached to a device that monitors acidity. Your baby might need to stay in the hospital while being monitored.
- X-rays. These images can detect abnormalities in the digestive tract, such as an obstruction. Your baby may be given a contrast liquid (barium) from a bottle before the test.
- Upper endoscopy. A special tube equipped with a camera lens and light (endoscope) is passed through your baby's mouth and into the oesophagus, stomach and first part of the small intestine. Tissue samples may be taken for analysis. For infants and children, endoscopy is usually done under general anaesthesia.

Health-care professionals usually ignore or disregard the effects of breastfeeding, tethered oral tissues and how this can affect infant reflux.<sup>8</sup> Pain, distended stomachs, sleepless nights all may be prevented or resolved by a simple, safe, fast and drugless treatment in office using dental lasers (Figure 2).

### **Obstructive sleep disordered breathing**

The second commonly presenting symptom with infants that have tethered oral tissues is airway problems.<sup>9</sup> Obstructive sleep-disordered breathing or obstructed sleep apnoea can be a problem for many infants. Sleep-disordered breathing is a term used to describe a series of signs and symptoms including snoring, upper airway resistance syndrome, obstructive hypopnea syndrome, and OSA.<sup>10</sup> Sleep-disordered breathing in children should be considered public health emergency, given the increasing rates of obesity and hyperactivity being seen in children.<sup>11</sup> Another symptom that may be attributed to an infant's failing to adequately get nutrition from breastfeeding is a diagnosis of failure to thrive This may be due an increased effort to breath resulting in an increase in caloric expenditure. A reduction in the production of growth hormone during fragmented sleep may contribute further to poor growth. When we look at the suggested symptoms as causes for OSDB, there again is no mention of tethered oral tissues except for the American Academy of Pediatrics obstructive sleep apnoea (OSA) guidelines where they added:<sup>12</sup> Assess tongue positioning as it may contribute to obstruction.

## Differential Diagnosis of obstructive sleep apnoea in Children<sup>9</sup>

1. Adenotonsillar hypertrophy
2. Nasoseptal obstruction
3. Enlarged soft palate or uvula
4. Macroglossia
5. Hypotonic pharynx
6. Lingual tonsils
7. Laryngeal abnormality (e.g., lymphatic malformation)
8. Micrognathia
9. Maxillary hypoplasia
10. Obstructive sleep apnoea
11. Suggested treatments

A delay in treatment of sleep disordered breathing (SDB) children may be caused by several factors and may result in serious consequences:

1. Delayed growth;
2. Neurocognitive and behavioural dysfunction;
3. Cardiorespiratory failure.

Adenotonsillectomy is suggested the treatment of choice, or continuous positive airway pressure may be suggested for infants who are not candidates for surgery. With the devastating effects sleep disorders can have on children and their families, the paediatric dentists must recognize obvious symptoms.

In October 2017, the American Dental Association (ADA) adopted a policy on dentistry's role in treating sleep-breathing disorders including obstructive sleep apnoea (OSA). It emphasizes that all dentists should be educated and able to screen for sleep-breathing disorders. Another point made in the policy is dentists treating sleep-related breathing disorders should stay up-to-date on the disorders and training in dental sleep medicine with continuing education.

The American Academy of Pediatric Dentistry (AAPD) recognizes that obstructive sleep apnoea (OSA) occurs in the paediatric population.<sup>12</sup> Undiagnosed and/or untreated OSA is associated with cardiovascular complications, impaired growth (including failure to thrive), learning problems, and/or behavioural problems. In order to reduce such complications, AAPD encourages healthcare professionals to routinely screen their patients for increased risk for OSA.

### Policy statement

The American Academy of Pediatric Dentistry (AAPD) recognizes that there may be consequences of untreated

OSA. Therefore, the AAPD encourages health care professionals to:

- Screen patients for snoring and sleep-related breathing disorders.
- Screen patient for OSA.
- Assess the tonsillar pillar area for hypertrophy.

### **Assess tongue positioning as it may contribute to obstruction**

- Recognize obesity may contribute to OSA.

The clinical consequences of disrupted sleep architecture and hypoxemia as a result of sleep disordered breathing in children are becoming defined in the paediatric population.<sup>13</sup> Neurodevelopmental complications include developmental delay, poor school performance, hyperactivity, aggressive behaviour, and social withdrawal (Figure 3). Excessive daytime sleepiness may interfere with school performance and there is increasing evidence that children often develop cognitive, emotional, and behavioural consequences of inadequate sleep.<sup>13</sup> The association of snoring with inattention and hyperactivity suggests that SDB could be the cause of inattention and hyperactivity in some children. One study suggests that 81 per cent of snoring children who have attention-deficit/hyperactivity disorder (ADHD) (25 per cent of all children with ADHD) could have their ADHD eliminated if their sleep disordered breathing was effectively treated.<sup>14</sup> Numerous clinicians and clinical investigators have commented on how some sleep-deprived children can manifest cognitive and behavioural changes mimicking attention-deficit/hyperactivity disorder. More than two million children in the United States have obstructive sleep apnoea or other debilitating sleep disorders, yet only 20 per cent of paediatricians screen for these problems.

An infant's brain is growing rapidly in the first 90 days after birth, the growth rate was approximately 1 per cent per day slowing to 0.4 per cent/day by the end of the first three months, when the brain reached just more than half of elderly adult brain volume.<sup>15</sup> Overall growth in the first 90 days was 64 per cent. Thus, it is a critical time for the infant not to have any airway blockage and reduced oxygen flow to the developing brain from an ankylosed tongue. The paediatric dentist again is in the unique position to evaluate and treat any tethered oral tissues he or she determines is causing and obstructed sleep.<sup>16</sup> It is necessary for the physician to now acknowledge the effect of the tethered oral tissues and work with the paediatric dentist to ensure the infant can grow properly with no airway blockage from the ankylosed tongue.<sup>17</sup> Allowing these ties to go untreated

because of a lack of training results in long term emotional problems for many of these infants.

Studies show that a short lingual frenum or ankyloglossia left untreated at birth is associated with sleep disordered breathing at a later age.<sup>18-22</sup> Revising the lingual attachment and any other tethered oral tissues at birth are beneficial for the infant's growth and development and will improve the child quality of life as he or she matures.

## Conclusion

There is adequate evidence in the medical and dental literature to suggest that paediatricians, ENTs, and the paediatric dentist need to properly assess, diagnose and treat infants presenting with symptoms due to a poor or shallow latch during breastfeeding or bottle feeding. A poor latch during infant feeding resulting in swallowing of air leading to the misdiagnosis of adult reflux and treatment with dangerous adult anti-reflux medications. Infants develop air induced Reflux (AIR). The cure is often a simple in office surgical procedure using the latest safe and effective technology of lasers, allowing the Infant achieves a secure tight attachment onto the mother's breast during breastfeeding. Lasers are safe, quick, and when used in a well-trained surgeon are free of complications.

Obstructive sleep disordered breathing can be another consequence of the ankylosed tongue and if allowed to go untreated can allow developmental problems which can last a life time. Early intervention can potentially intercept this from occurring. The inclusion and understanding of how the tongue can play apart in these medical conditions. The professions of dentistry and medicine are continuing to merge closer together in the treatment of infants.

---

## References

1. NIH Eunice Kennedy Shriver National Institute of Child Health and Human development. [www.pediatrics.org/cgi/doi/10.1542/peds.2011-3552](http://www.pediatrics.org/cgi/doi/10.1542/peds.2011-3552) doi:10.1542/peds.2011-3552
2. USDA WIC Breastfeeding Support Steps and signs of a good latch.
3. Kotlow L. Infant reflux and aerophagia associated with the maxillary lip-tie and ankyloglossia (tongue-tie). *Clin Lact.* 2011;2:4.
4. Siegel S. Aerophagia induced reflux in breastfeeding infants with ankyloglossia and shortened maxillary labial frenula (tongue and lip tie). *Int J Clin Pediatr North Am* 2016.
5. Kotlow LA. The Breastfeeding Dilemma: Misdiagnosed TOTS or Just Ignoring their Existence? *Med Case Rep J* 2018;1:102.
6. Lyon J. Study Questions Use of Acid Suppressors to Curb Mild Infant Reflux. *JAMA.* 2017;318(15):1427-1428. doi:10.1001/jama.2017.12160
7. AAP Releases Guideline for the Management of Gastroesophageal Reflux in Children *Pediatrics.* 2013;131:e1684–e1695.
8. Lawrence Kotlow. "Breastfeeding and Tethered Oral Tissues: Air Induced Reflux and Obstructive Sleep Apnea". *EC Paediatrics* 3.3 2016:356-365.
9. Chan J, Cleveland Clinic Foundation, Cleveland, Ohio, Edman J M.D Fairview Hospital, Cleveland, Ohio, Koltai, P Cleveland Clinic Foundation, Cleveland, Ohio 1148. Obstructive Sleep Apnea in Children-AMERICAN FAMILY PHYSICIAN [www.aafp.org/afp](http://www.aafp.org/afp) VOLUME 69, NUMBER 5 / MARCH 1, 2004.
10. Chervin RD, Archbold KH, Dillon JE, et al. Inattention, hyperactivity, and symptoms of sleep-disordered breathing. *Pediatrics.* 2002;109:449–56.
11. Sleep disordered breathing in infants and children: a review of the literature. Ivanhoe JR, Lefebvre CA, Stockstill JW. *Pediatr Dent.* 2007 May-Jun;29(3):193-200. Review.
12. OSA: REFERENCE MANUAL V 40 / NO 6 18 / 19.
13. Brouillette RT, Morielli A, Leimanis A, et al. Nocturnal pulse oximetry as an abbreviated testing modality for pediatric obstructive sleep apnea. *Pediatrics.* 2000;105:405–12.
14. Chervin RD, Dillon JE, Basseti C, et al. Symptoms of sleep disorders, inattention, and hyperactivity in children. *Sleep.* 1997;20:1185–1192.
15. Holland D, Chang L, Ernst TM, et al. Structural growth trajectories and rates of change in the first 3 months of infant brain development. *JAMA Neurol.* 2014;71(10):1266–1274. doi:10.1001/jamaneurol.2014.1638
16. Huang YS, Quo S, Berkowski JA, et al. Short lingual frenulum and obstructive sleep apnea in children. *Int J Pediatr Res.* 2015;1:1.
17. Tan HL, Gozal D, Kheirandish-Goza L. Obstructive sleep apnea in children: a critical update. *Nat Sci Sleep.* 2013;5:109–123.
18. Guilleminault C, Huseni S, Lo L. A frequent phenotype for paediatric sleep apnoea: short lingual frenulum. *ERJ Open Res.* 2016;2(3):00043-2016.
19. Bonuck K, Freeman K, Chervin RD, et al. Sleep-disordered breathing in a population-based cohort: Behavioral outcomes at 4 and 7 years.

Pediatrics. 2012;129(4):e857–e865. doi:  
10.1542/peds.2011-1402

20. Kotlow L. Infant reflux and aerophagia associated with the maxillary lip-tie and ankyloglossia. Clin Lact. 2011;2(4):25–9.
21. Kotlow L. TOTS-tethered oral tissues the assessment and diagnosis of the tongue and upper lip ties in breastfeeding. Journal of Oral Health 2015 March.
22. Kotlow L. Using the Erbium: YAG laser to correct abnormal lingual frenum attachments in newborns. J Acad Laser Dentistry. 2004;12:3.

### **PEER REVIEW**

Not commissioned. Externally peer reviewed.

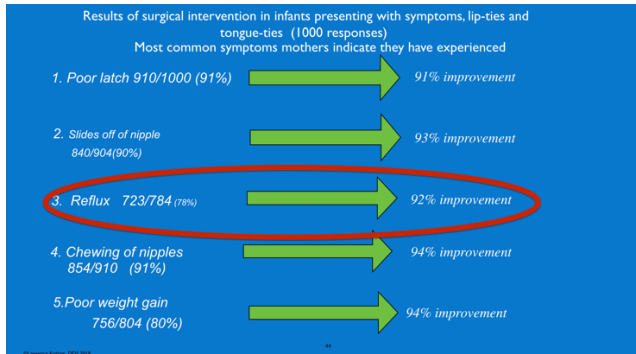
### **CONFLICTS OF INTEREST**

The author declares that I have no competing interests.

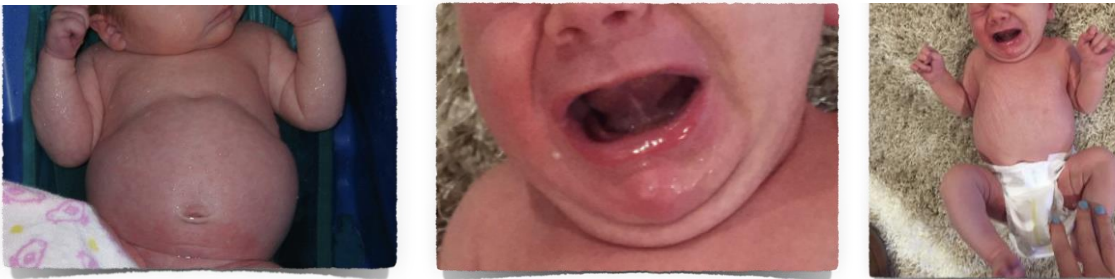
### **FUNDING**

None

**Figure 1: Results of parental post-surgery questioner showing over 90 % resolution of infant air induced reflux**



**Figure 2: Abdominal distention due to swallowing air related to a poor latch due to a severe ankyloglossia**



**Figure 3: How obstructive sleep apnea can affect quality of life when not resolved**

