

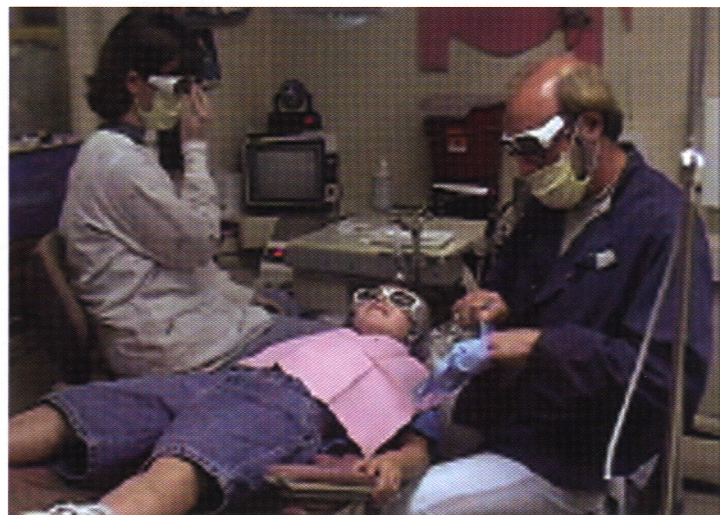The Use of the Erbium Hard & Soft Tissue Laser in the Pediatric Dental Practice

Lawrence Kotlow, DDS, Albany, NY

518.489.2571

As a "primary health care professional of the oral cavity," the pediatric dentist has the unique opportunity to oversee many of the changes in growth and development that children go through as the hard and soft tissues evolve. Today's modern pediatric practice specializes in the prevention, interception and correction of developmental abnormalities sometimes found in these structures.

Initial examination of children should begin approximately six months after the first teeth appear. This is usually about 12-14 months of age. Soft tissue abnormalities such as ankyloglossia, abnormal lingual frenum attachments, may interfere with nursing or normal development. In older children, gingival hypertrophy, pericoronal infections, exposure of unerupted teeth, or aphthous ulcer pain may all require early intervention.



Dr. Kotlow Preparing For Laser Treatment

Prior to the introduction of managed care, most oral surgical procedures were referred to the oral surgeon, who would place the children into the operating room and keep them overnight. This practice would often place the dentist at odds with the physician and parents who were reluctant to place the child under general anesthesia for an elective procedure. In order to intercept such soft-tissue problems as tongue-tie releases (frenectomies), I began using an electro-surgical unit and local anesthesia in the office to deal with these concerns. Electro-surgery provided a fast, clean method for treating these problems, and the results were excellent. However, two major drawbacks to this modality were post-operative discomfort and prolonged healing times. These were especially problems in very young children. In the area of caries removal and cavity preparations, I began using air abrasion over six years ago with excellent results doing minimally invasive preparations. The only drawback was the spray of powder outside the oral cavity.

In my effort to provide my patients with the newest, safest and most up-to-date care, I am always looking for new procedures or equipment.

Until recently, I was reluctant to incorporate

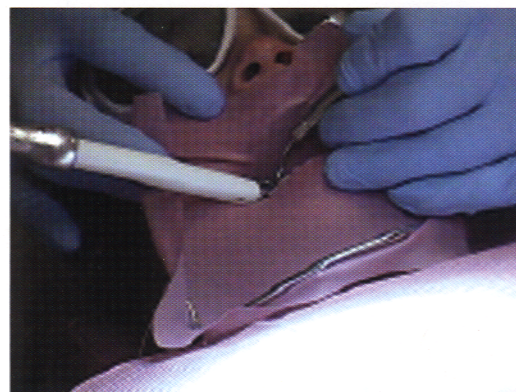
a laser into my practice, due to concerns about quick movements causing serious injury to the patient. I had tried a soft tissue laser for a short period of time, but I felt it was of little value to my pediatric practice. That changed this year with the introduction of the Erbium:YAG laser into my practice.

My decision to purchase an Erbium:YAG laser (the DELight dental laser from Continuum, Santa Clara, CA) provided me with the opportunity to compare my existing treatment methods (electro-surgery, air abrasion) with the laser. The DELight dental laser gives me the ability to change both the repetition rate of the pulses and the millijoules per pulse output to meet the needs of the specific child and procedure. The ease of handpiece maneuverability and the availability of multiple tip styles provide a wide range of power and comfort for both hard and soft tissue procedures.

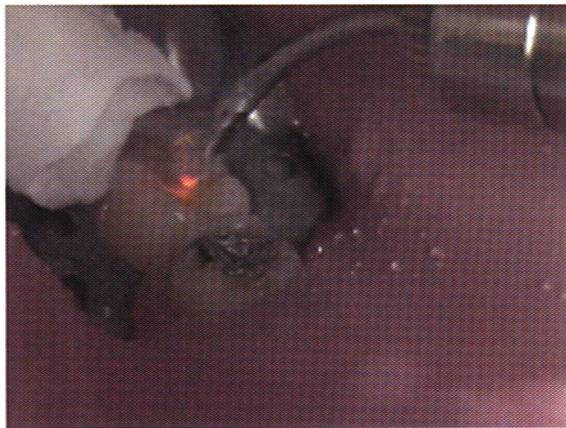
The results of my experiences revealed the following:

HARD TISSUE: In most cases the Erbium laser and air abrasion are very similar. The laser cuts without the spread of powder, which is a real benefit. When comparing cutting, there is more control with the laser of the depth of cut in the restoration of the anterior teeth with class III decay. Also, since the laser is end-cutting only at the tip, Class II preparations are quicker and easier to complete than with air abrasion.

Procedures such as sealant preparation or cutting of enamel generally use settings of 20-30 Hz and 185 mJ. In most cases, no local anesthesia is required for dentinal or caries removal. In large carious lesions, initial access may be completed with the laser, gross caries removal with a slow speed drill, and final caries removal with the Erbium laser. Dentinal access is achieved with a setting of 20 Hz and 120-160 mJ, while caries removal is set at 10-20 Hz and 65-100mJ (or lower in anterior teeth).



Laser During Treatment



Laser In Use In Hard Tissue Procedure

SOFT TISSUE:
The results with the laser are similar to those with electro-surgery, with the additional major benefits of reduced healing

time, little to no tissue contraction post-operatively, little to no post-operative discomfort, and the reduction in the use of local anesthesia. In fact, I have completed tongue-tie revisions, maxillary frenectomies, mandibular frenectomies, and gingivectomies without the need for any local anesthesia.

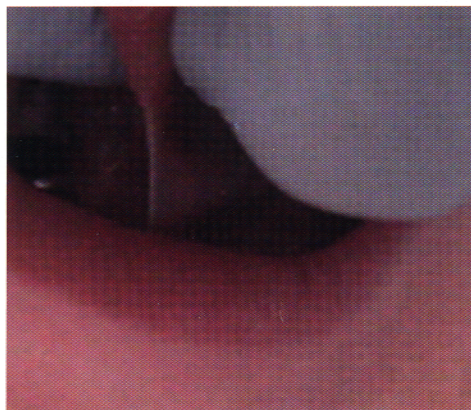
The settings used for soft tissue surgery begin at a low setting of 20 Hz and 50-90 mJ. During treatment, the energy per pulse can slowly be brought up to 70-120 mJ for most procedures. My tip selection for these types of procedures is either the straight short tip or the longer surgical tip. Bone removal between the maxillary central incisors is accomplished with no obvious post-operative problems.

POSITIVE PATIENT RESPONSES: In my experience, few parents have heard of, or understand the concept of air abrasion. However, the mere mention of the word "laser" brings about high expectations and quick acceptance. When presenting treatment plans, I am routinely asked if I will be using the laser. Interviewing the children immediately after completing restorative or surgical procedures almost always indicates that no discomfort was felt. Post-operative phone calls on the day of soft tissue surgery treatment, as well as discussions with the parents and patients at their one-week follow-up appointment indicate that most children require little to no pain medication after the local anesthesia wears off (if used).

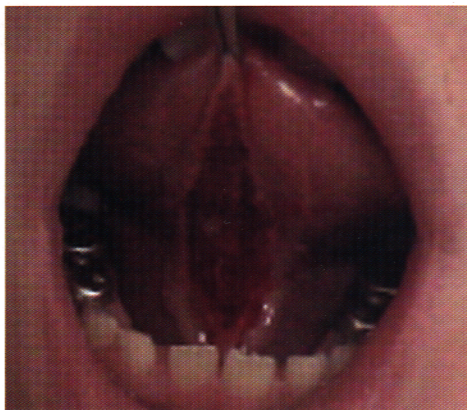
IN CONCLUSION, children can be safely treated using the Erbium laser for both caries removal and soft tissue surgical treatment. In most cases, caries removal will not require local anesthesia. Soft tissue surgical procedures usually require a reduced amount of local anesthetic

HARD TISSUE APPLICATIONS		SOFT TISSUE APPLICATIONS	
1	Sealant Preparation	1	Tongue-tie releases in newborn infants
2	Enamel caries removal	2	Tongue-tie releases in children for speech, orthodontic or periodontal problems.
3	Dentin caries removal	3	Maxillary frenectomies in the mix dentition stage to close diastemas.
4	Bone recontouring or removal in maxillary frenectomies	4	Maxillary frenectomies in nursing bottle decay cases.
5	Class I-V restorations	5	Mandibular frenectomies to improve gingival attachments.
		6	Pericoronal infections in erupting permanent molars.
		7	Removal of hypertrophic tissue in orthodontic patients.
		8	Reduction of hyperplastic patients due to Dilantin.
		9	Reduction of cheek scar tissue in children with limited bite opening, due to surgery or trauma.
		10	Elimination of pain in aphthous ulcer area.
		11	Exposure of unerupted teeth.
		12	Entering into the pulp of primary teeth.

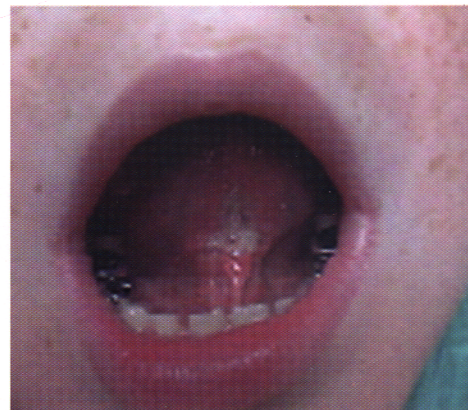solution, and patients display a significant reduction in both post-operative discomfort and healing time. The Erbium laser is an excellent addition to the pediatric dentist's practice



Tongue-Tied Patient Before Laser Surgery



Tongue-Tied Patient Immediately Post-Op



Tongue-Tied Patient 6 Days Post-Op