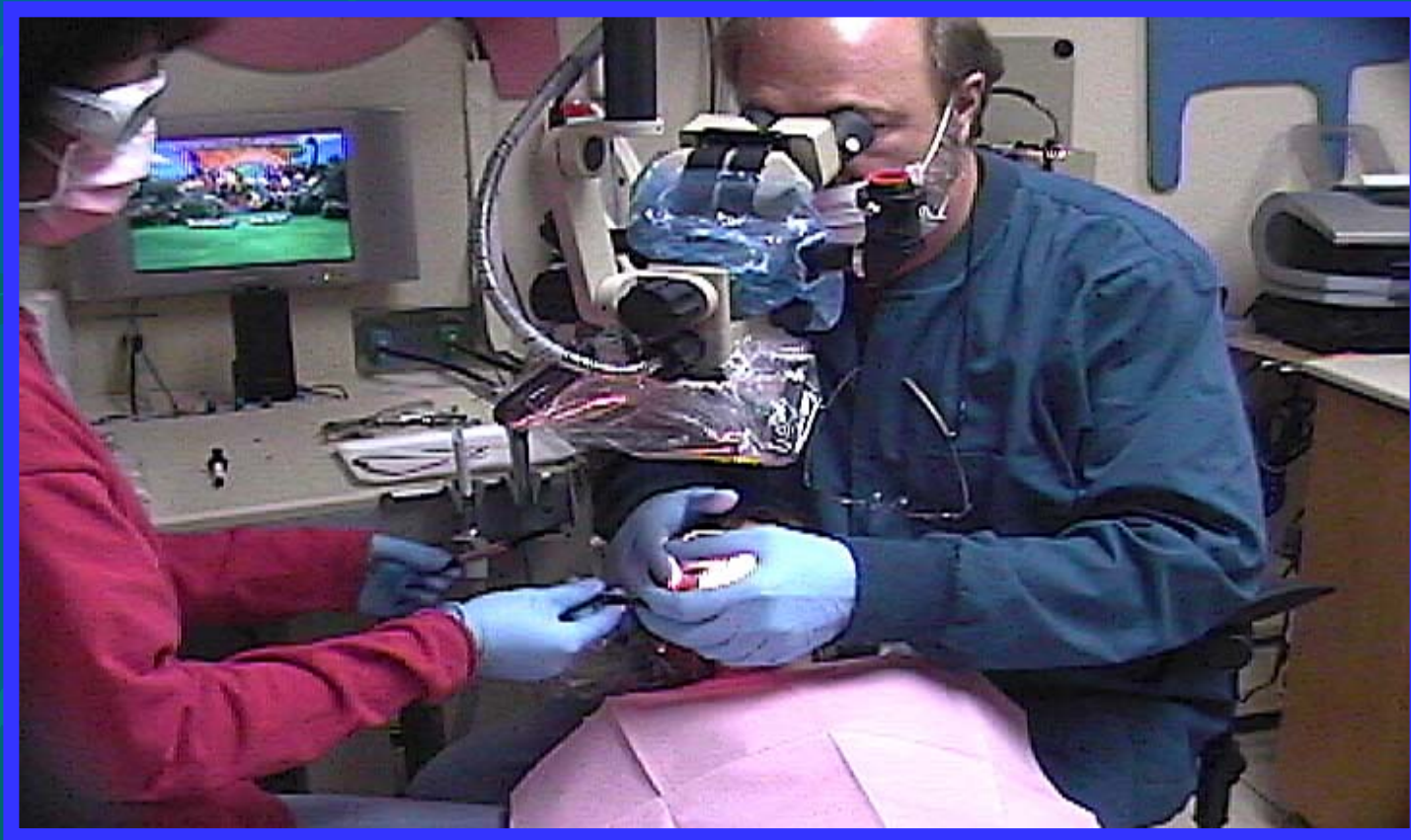

Pediatric Dental Care



Lawrence Kotlow DDS

Patient comfort and safety

1. All children are treated using the most up-to-date safe technology available.
2. All oral surgery treatments are completed using up to three different lasers.
3. The use of lasers promote healing and reduce post surgical discomfort.
4. Lasers eliminate the need for sutures in most patients.
5. All treatment is completed using microscopes to reduce damage to adjacent oral structures.
6. All needed x-rays are taken using computers and result in reduced patient exposure to radiation and reduced environmental contamination due to elimination of many of the materials and chemicals used when taking conventional dental x-rays.

Updates in Oral Pediatric Diagnosis

Ankyloglossia or Tongue Ties

Preventive and interceptive medical/dental treatments



Lawrence Kotlow DDS

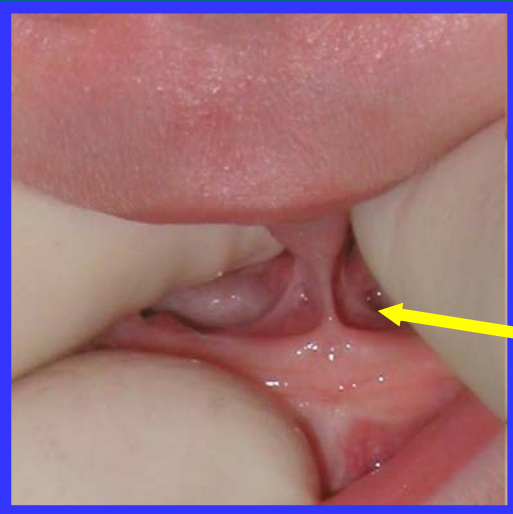
Board Certified Specialist In Pediatric Oral Care Since 1974

Advanced Proficiency in Erbium Laser Surgery by the Academy of
Laser Dentistry

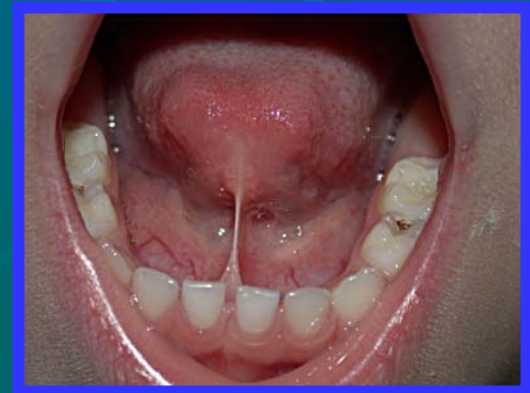Is Your Child Tongue-Tied ?



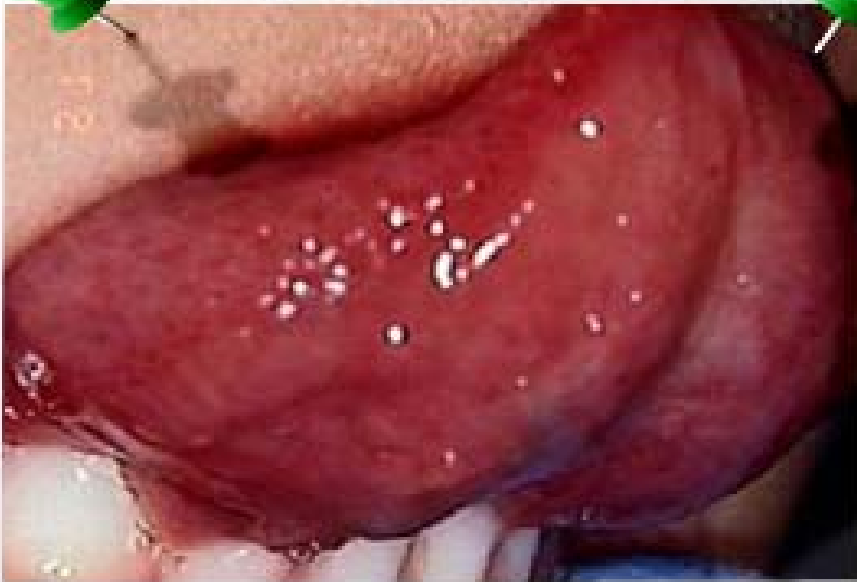Ankyloglossia: An abnormal attachment of the tissue under the tongue.



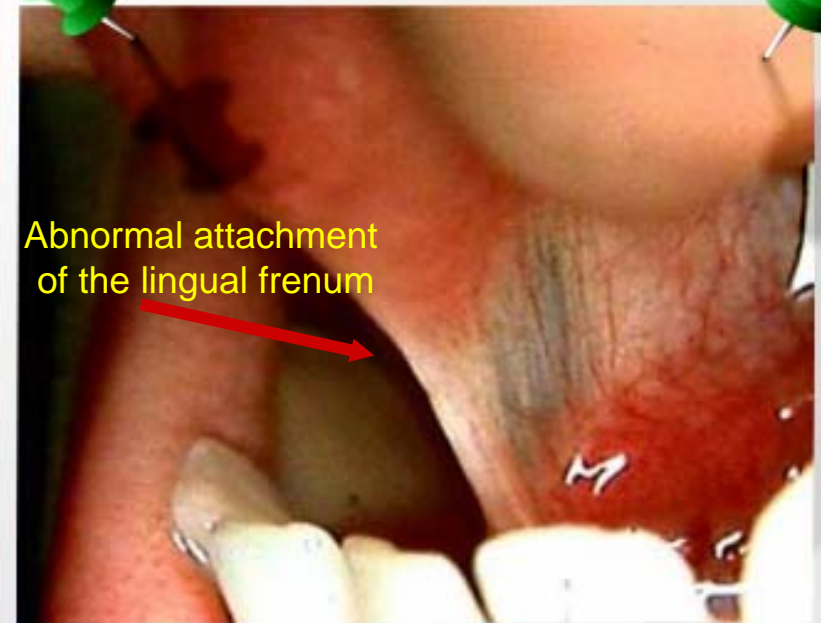
Short Lingual frenum on new born



Updates in Oral Pediatric Diagnosis



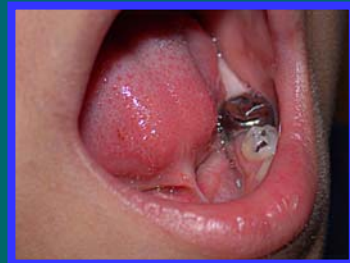
Normal anatomy of the underside of a child's tongue




Abnormal attachment of the frenum on the underside of tongue

Is Your Child Tongue-Tied ?

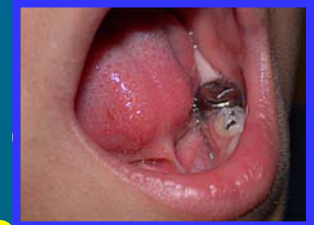“Traditional teaching has been that the tongue tie is of little relevance, will have no adverse oral effects, and can be ignored.”



■ Is Your Child Tongue-Tied



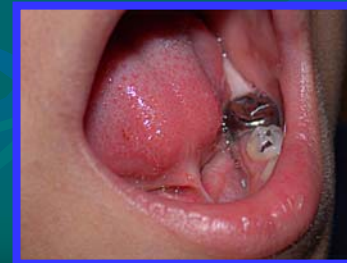- The significance & treatment of a
- tongue-tie is often misunderstood and misdiagnosed due to old medical misconceptions and methods for treating condition. This is especially true when the recommendation in the past often required placing a child into the operating room under a general anesthesia for an elective procedure.



Is Your Child Tongue-Tied ?


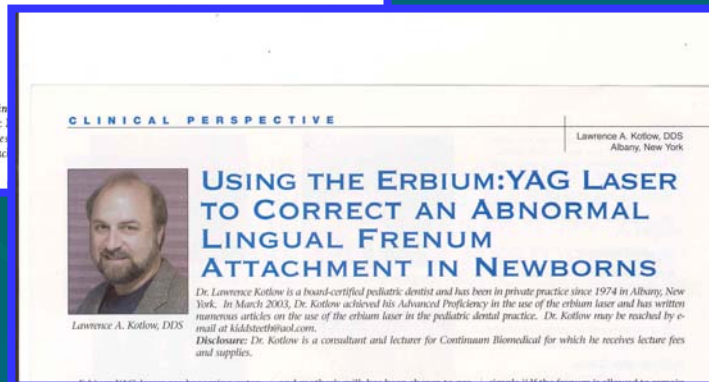
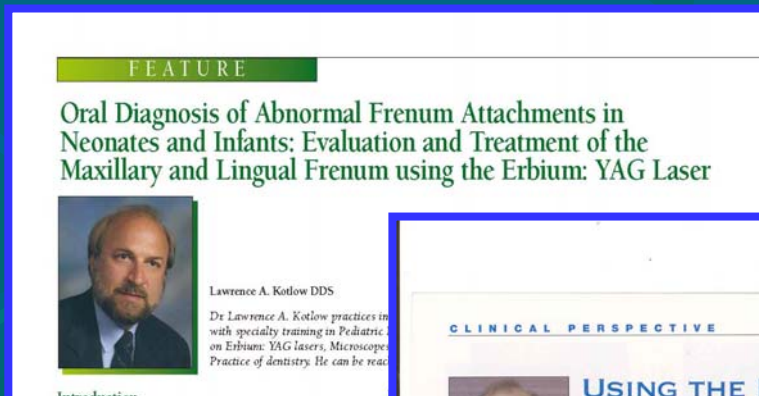
Updated oral health information:

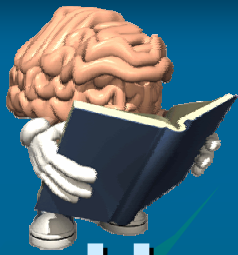
- "Tongue tie, by interfering with tongue mobility, can exert a harmful effect on many aspects of life."



Articles and text books

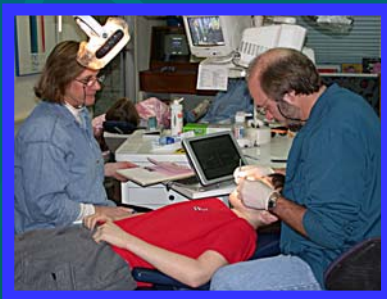■ To assist healthcare professionals diagnose and treat problems associated with tongue ties. I have published articles and contributed a chapter the well respected text “Dental Clinics of North America” , based on my experience and success in treating this condition. All of this information is available for downloading from my web site.



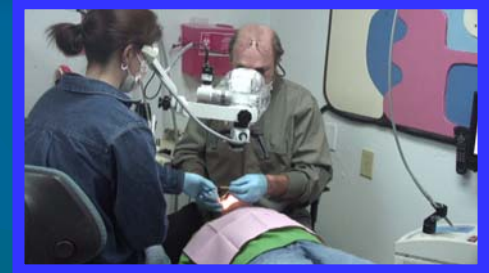


Updated diagnosis & treatment recommendations for tongue-ties

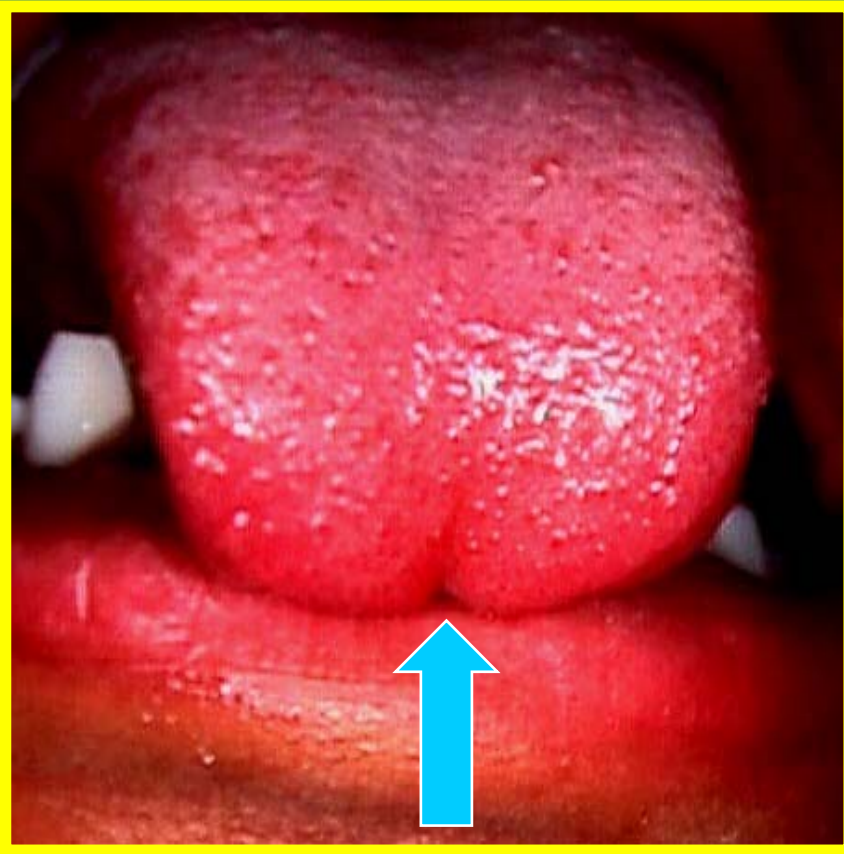- **Diagnostic Criteria used to determine when a**
- **Tongue –Tie requires revision.**



Diagnostic Criteria

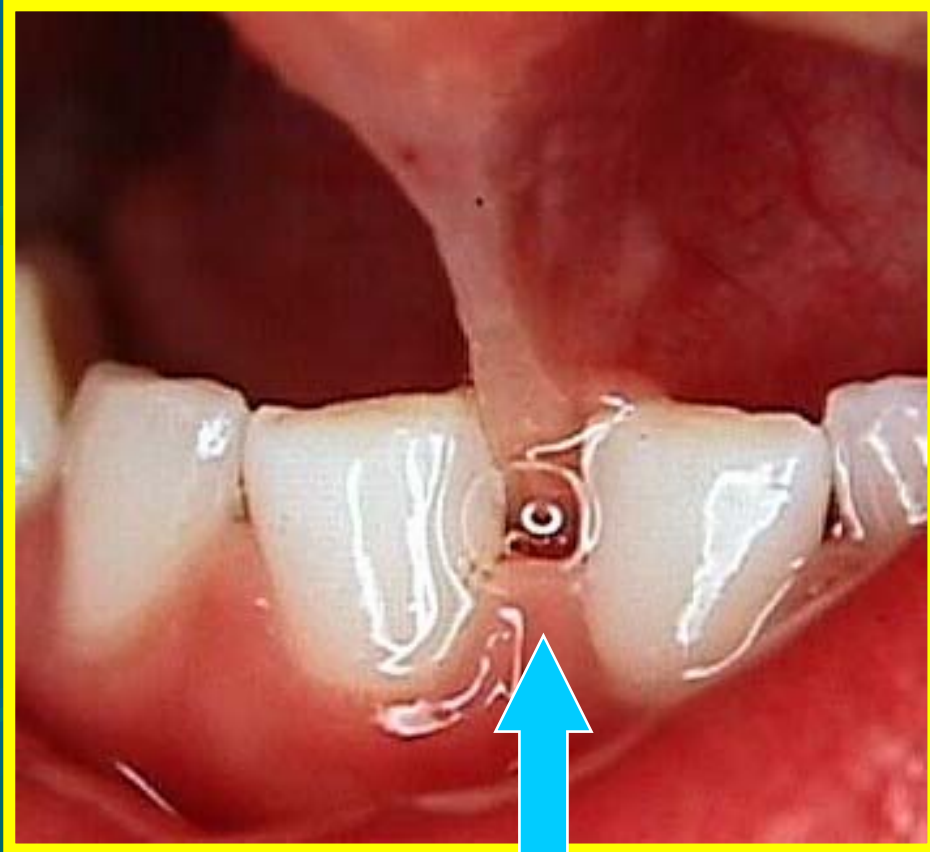
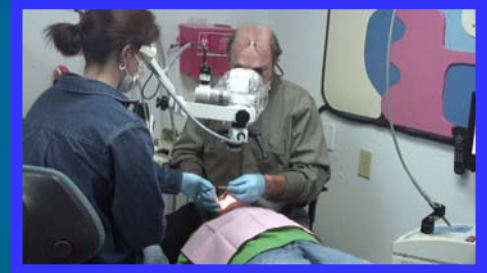

 The tip of the tongue should be able to protrude outside the mouth without causing clefting of the front border of the tongue.



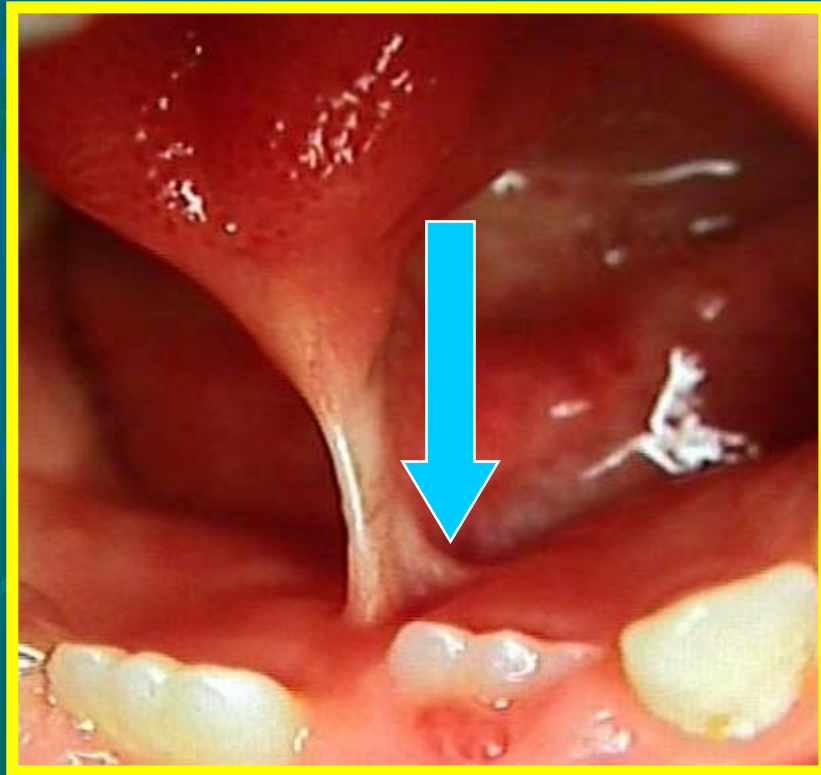
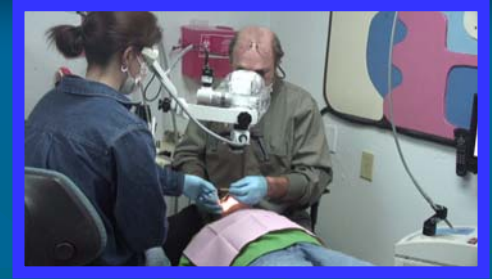Cleft of border of tongue


Diagnostic Criteria



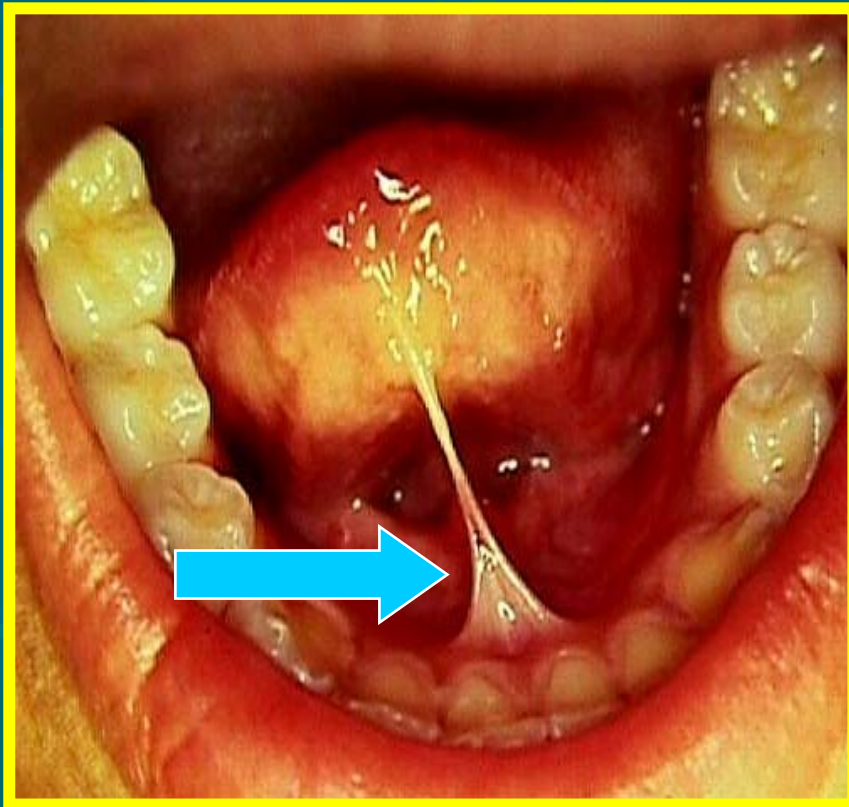
- ❏ **The lingual attachment should not create a diastema (gap) between the lower front teeth.**

Diagnostic Criteria



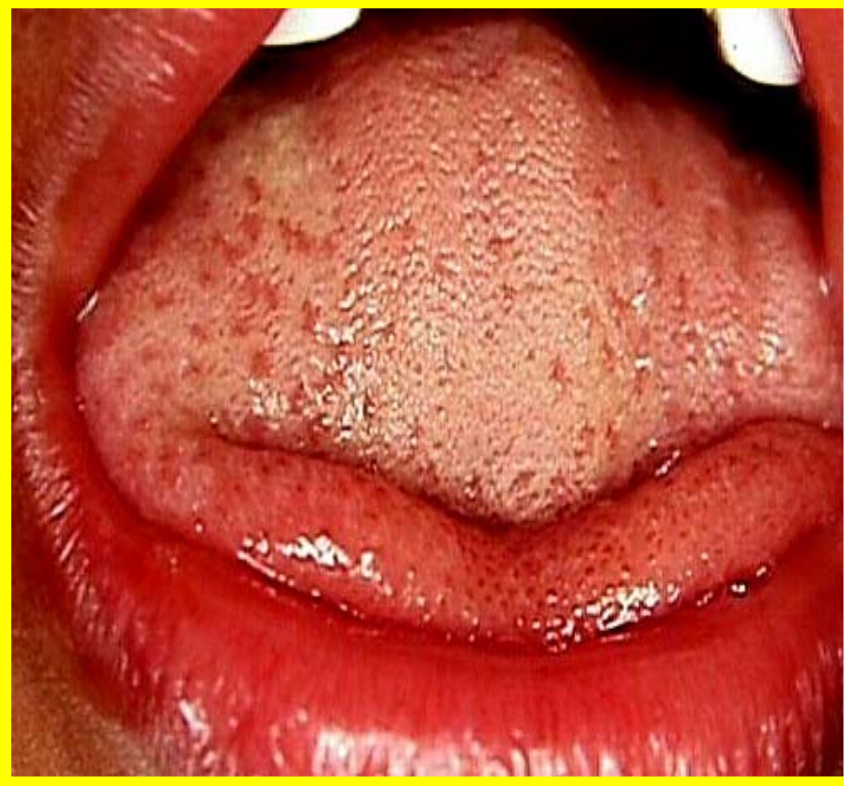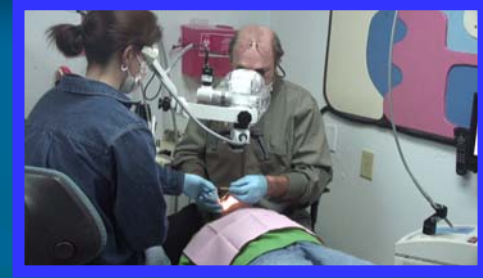 **The lingual attachment should not cause excessive force on the lower front teeth causing them to tip backward.**

Diagnostic Criteria



- ☰ **The lingual attachment should not cause severe blanching of the gum tissue behind the lower front teeth.**

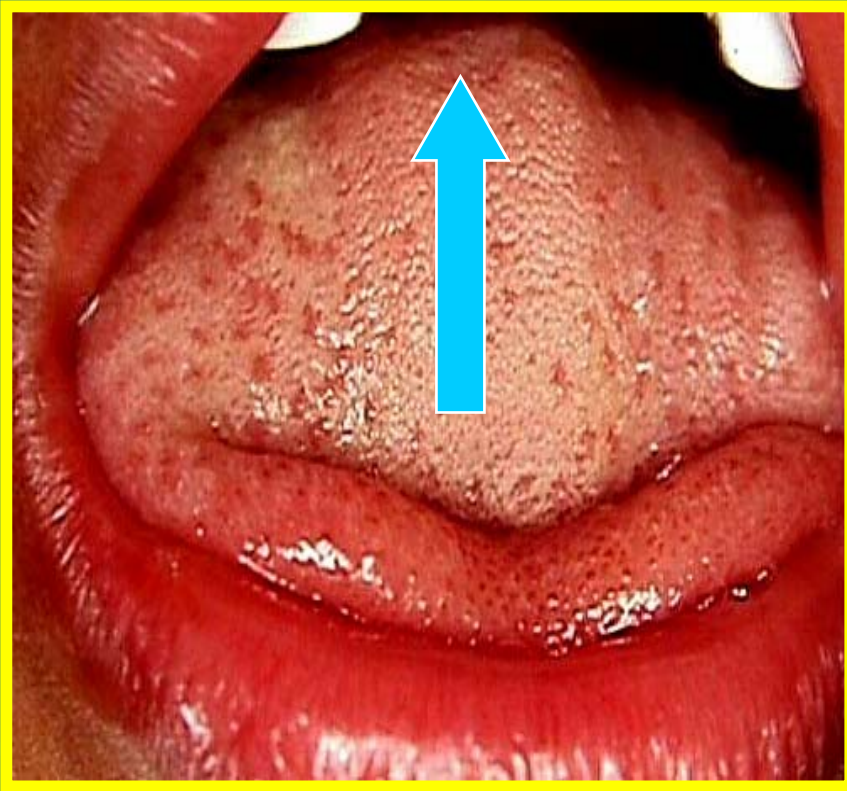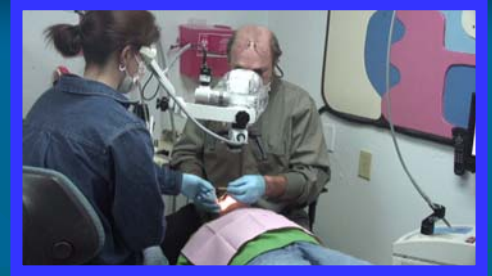Diagnostic Criteria



- ☰ **The lingual attachment should not prevent a normal swallowing pattern. The tongue should be able to lick the lips.**

Without the free movement of the tongue many food particles may not be removed by the tongue's normal sweeping action and correct movement of oral fluids.

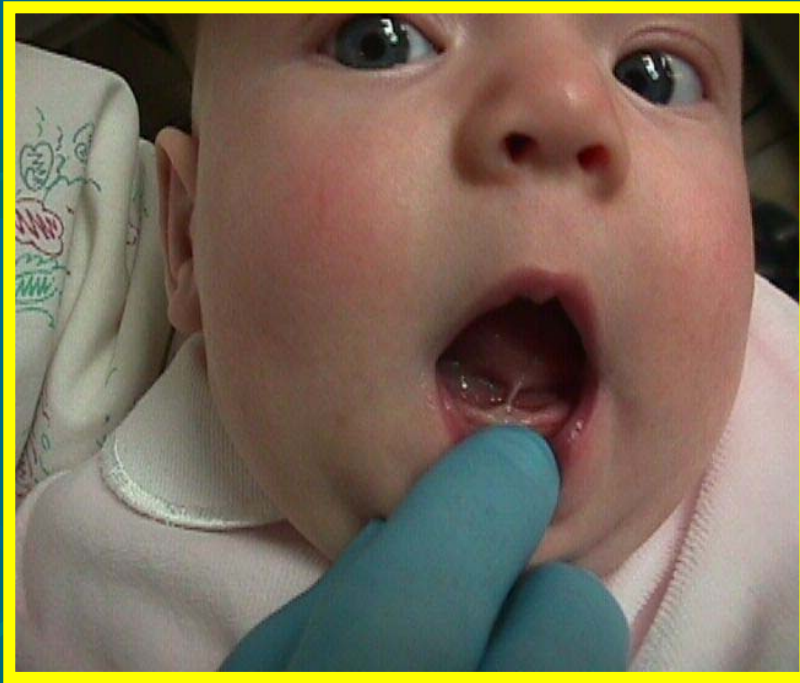Diagnostic Criteria




- ☰ **The lingual attachment should not prevent a normal swallowing pattern. The tongue should easily touch the roof of the mouth.**

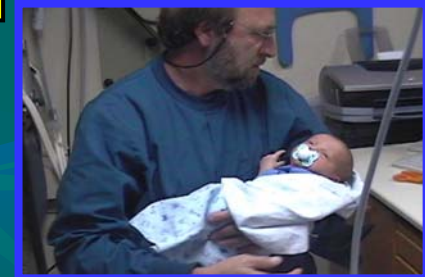Diagnostic Criteria

Please visit my web site or the Academy of Pediatrics web site for more valuable information concerning nursing



 The lingual attachment should not interfere with nursing or cause mothers pain

Nursing mother's can suffer nipple damage, pain or mastitis,



Diagnostic Criteria



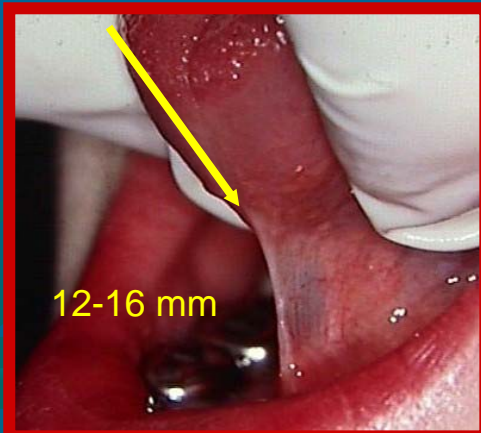
An abnormal lingual attachment can interfere with certain eating pleasures !

Diagnostic Criteria

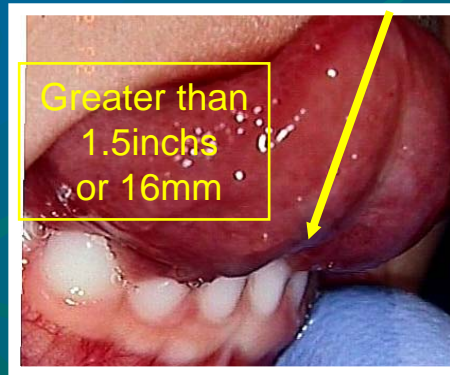


Certain Social Activities

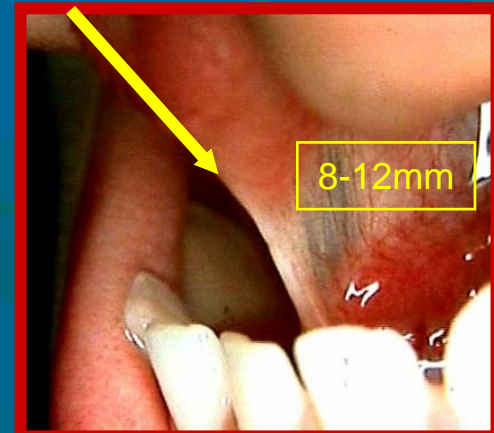
Classifications of Tongue-Ties



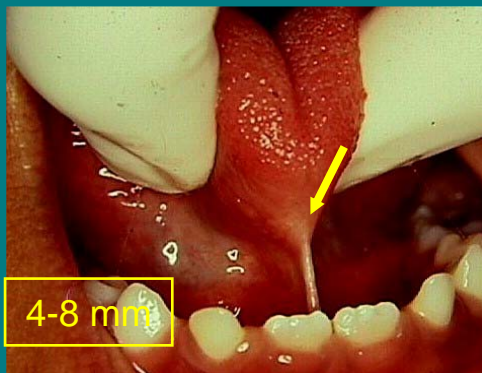
**CLASS 1
MILD**



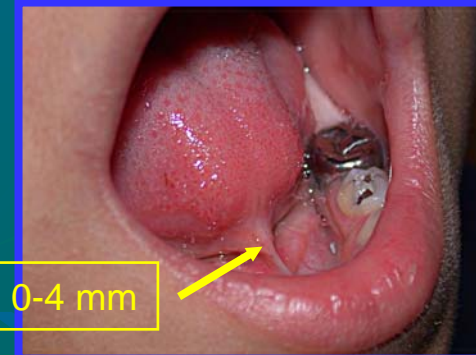
**NORMAL
RANGE OF
MOTION**



**CLASS II
MODERATE**



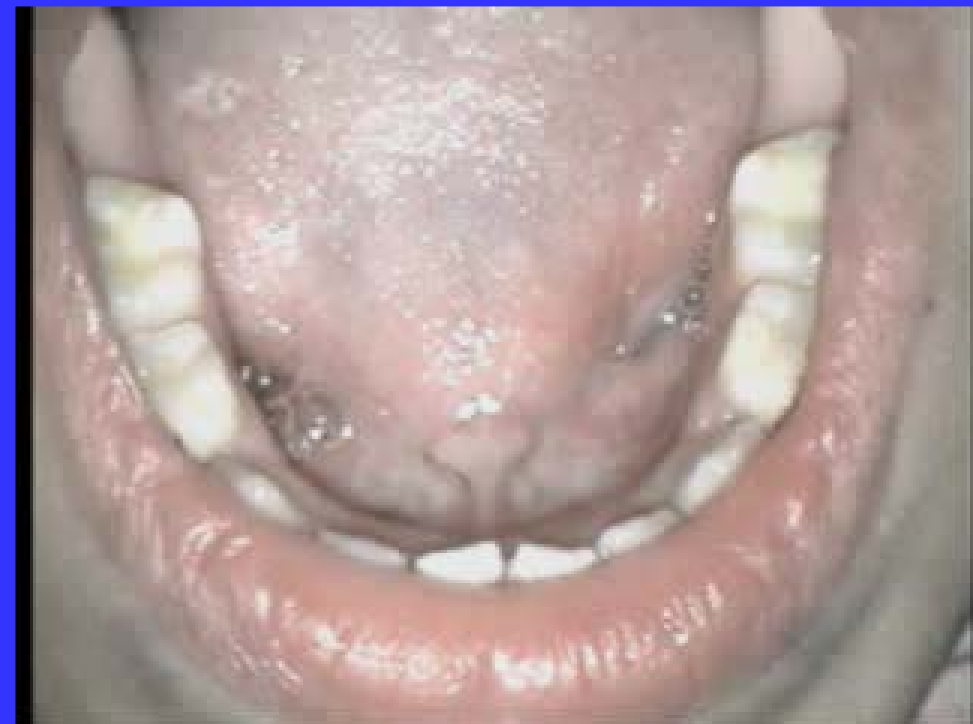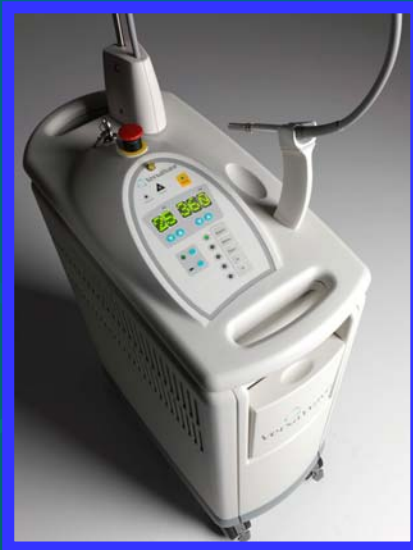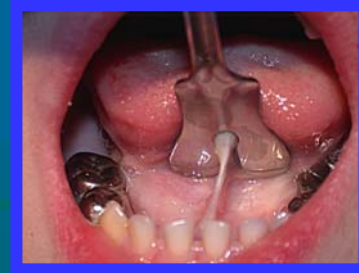CLASS III-SEVERE



CLASS IV- COMPLETE

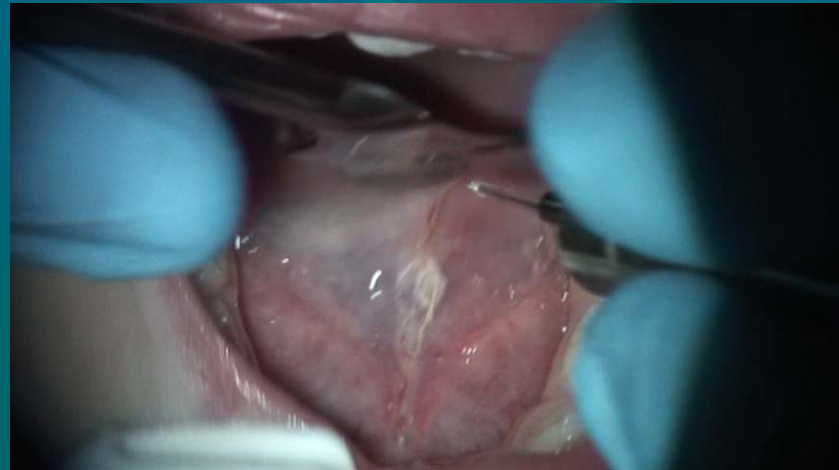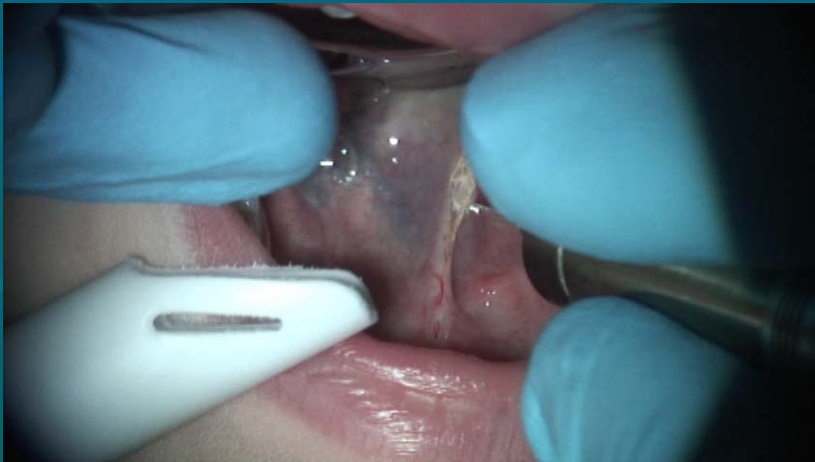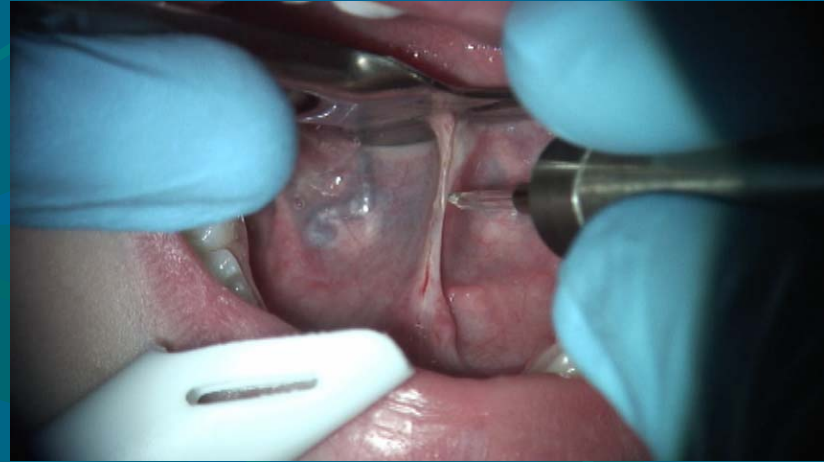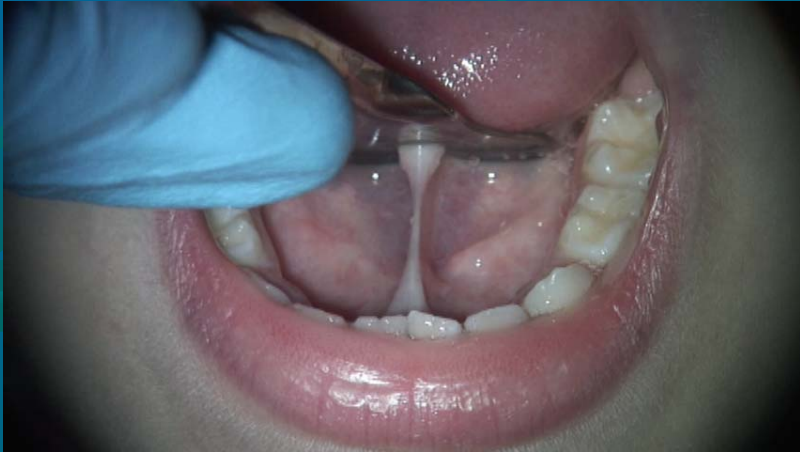In- Office Treatment and Release of Tongue-Tie

Local anesthesia : may or may not be required when revision is completed with the Erbium laser.



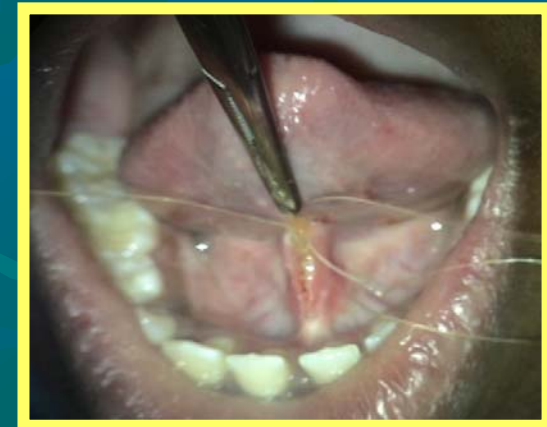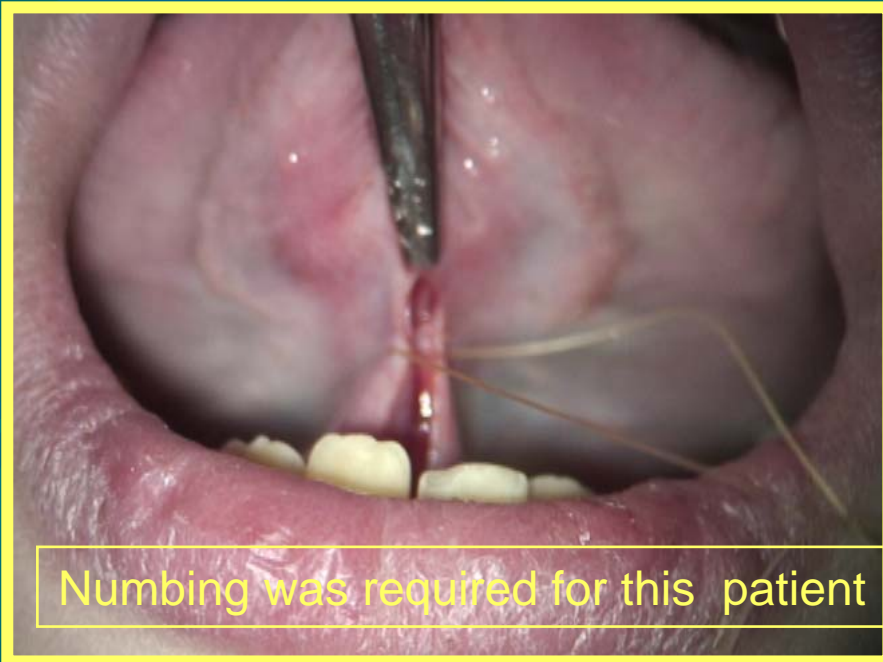Sutures are usually not required .

Revising the abnormal lingual frenum



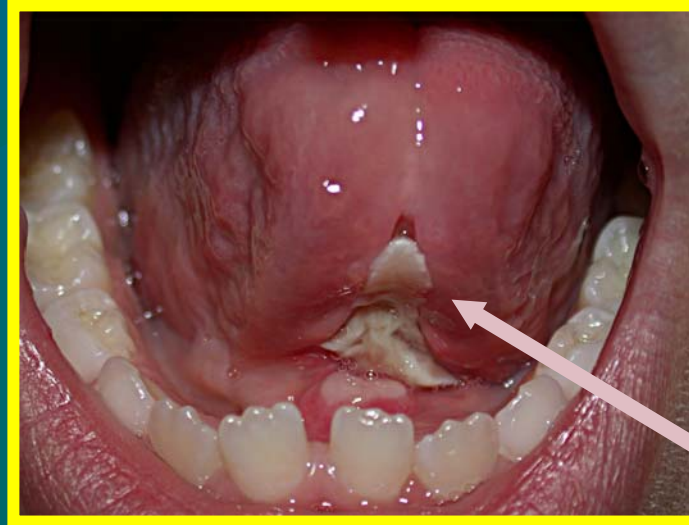
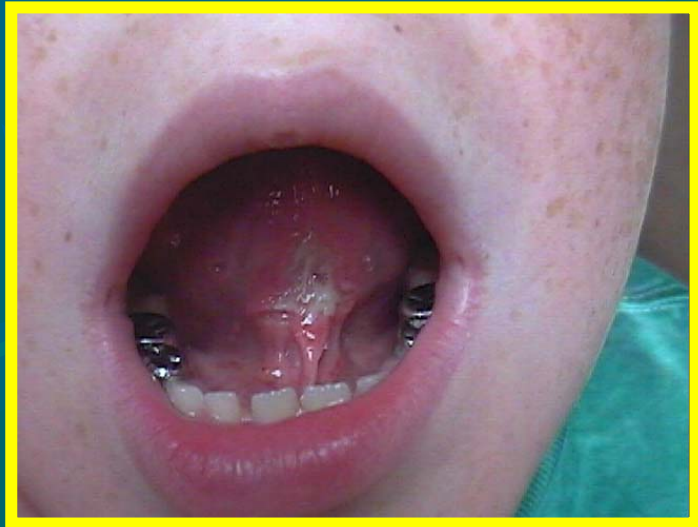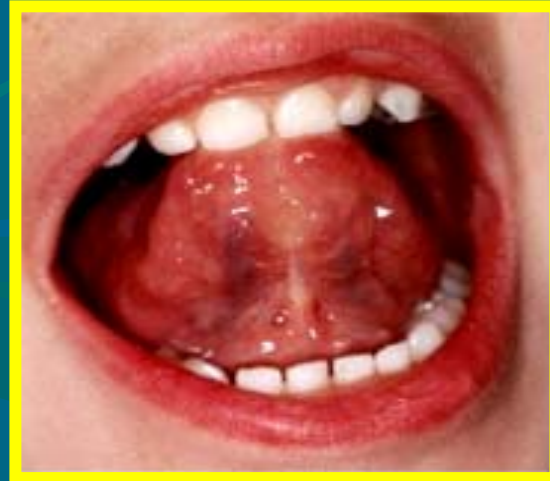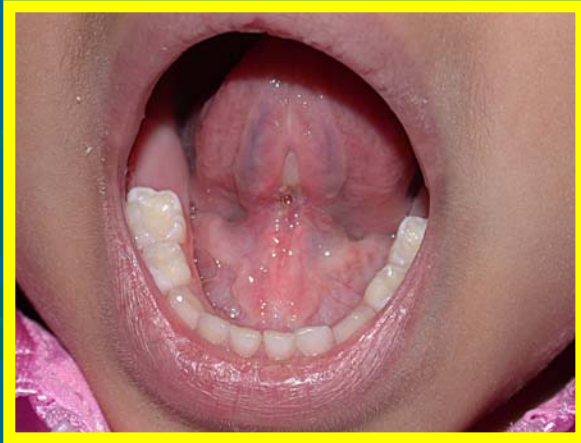No numbing was needed for this revision

More severe and thicker revisions may require numbing and one or two small sutures to prevent the frenum from reattaching



Placing a
dissolvable
suture to
prevent
reattachment

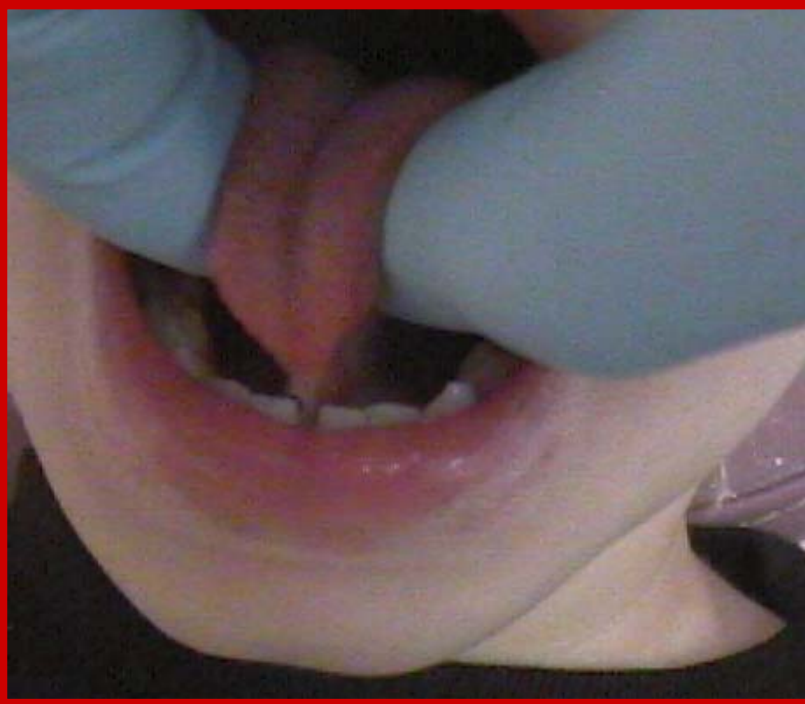
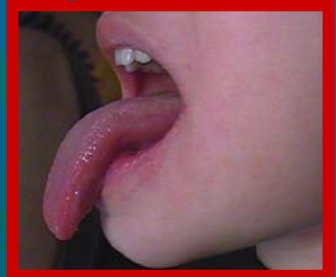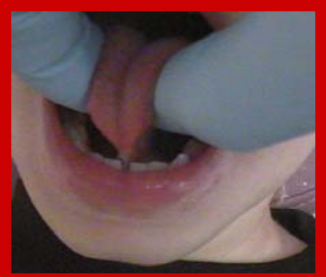
One week following laser surgery



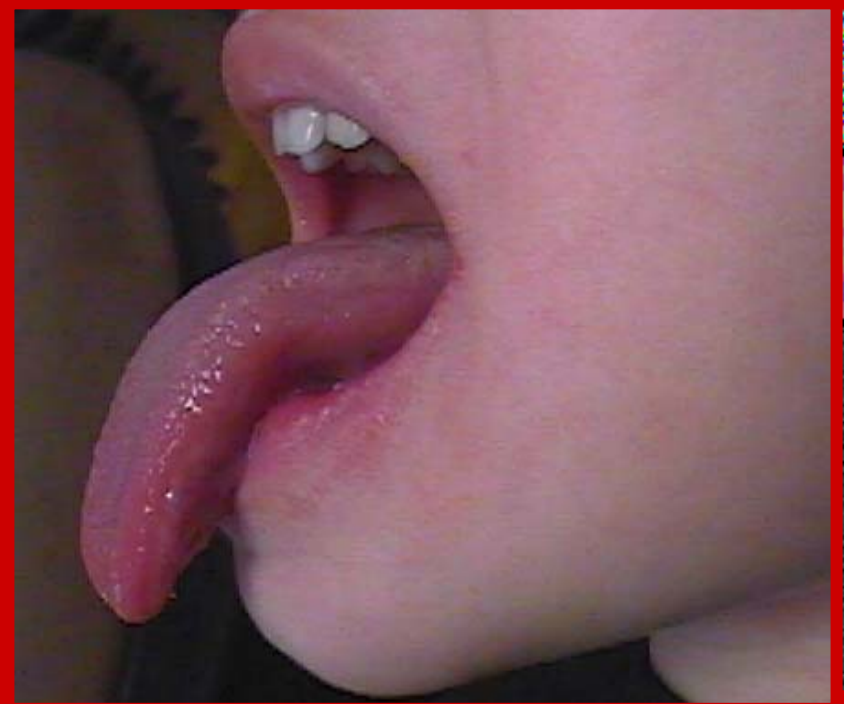Normal
oral
healing
area

Safe and Simple in-office treatment

Some or all discussed diagnostic criteria may be apparent upon examination

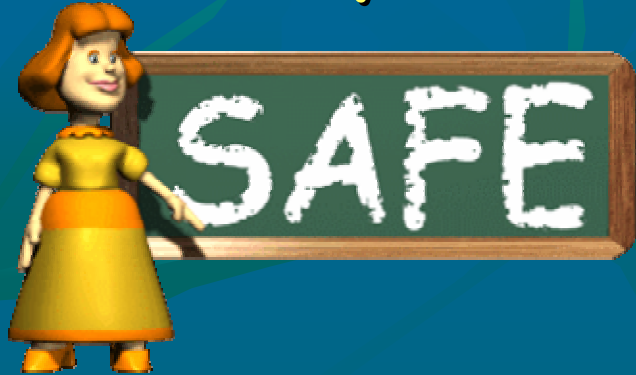

**Pretreatment
assessment.**



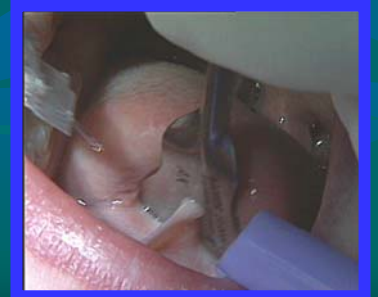**Immediately after laser
release in the office with
local anesthesia.**

Updates in Oral Pediatric Diagnosis today's most recent recommendations



Martin Glasson, Dept Pediatric
Surgery, New Children's
Hospital, Westmead NSW, Australia.

“Quality of life can be improved
by an operation which is simple,
brief, and virtually devoid of
complications.”



Is Your Child Tongue-Tied ?

Please feel free to discuss any questions concerning this abnormality and the treatment needed to correct the problem with Dr.Kotlow.

